



Integrated and Comprehensive  
Specialty and Emergency Care



## ***MEDVET CLINICAL REVIEW***

# **The Interlocking Nail for Fracture Repair in Small Animals**

**Matthew Barnhart DVM MS DACVS**

In 1939 Gerhard Küntscher used the first intramedullary pin in a human. He was striving to create a means by which to avoid the prolonged hospitalization and high complication rate associated with external coaptation and traction. His methods were eventually accepted worldwide after much controversy. The first interlocking nail (IN) was used in a human in 1968. The IN was developed with the intramedullary pin in mind but with the addition of locking screws to help prevent the rotational and compressive instability associated with other methods of intramedullary fixation.

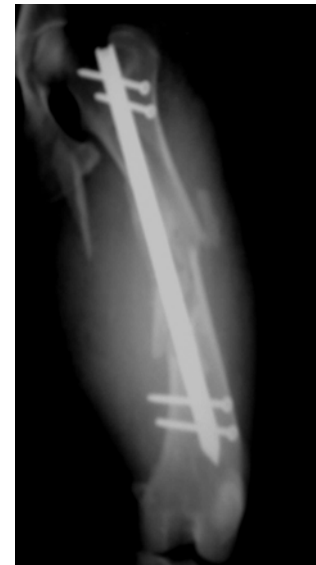Today, the IN is the implant of choice in human orthopedics for treatment of comminuted femoral, humeral, and tibial fractures. An IN system is now commercially available for use in small animals and preliminary clinical results have been very good. At MedVet we have had excellent results with this system.

The IN system is a valuable tool for treating small animal tibial, femoral, and humeral fractures; especially those that are comminuted. In these cases, adequate bone reconstruction may be impossible or cause extensive surgical trauma to surrounding soft tissue structures. Intramedullary pin fixation is a poor choice in such a situation because of inadequate rotational and compressive stability. While a bone plate can be used for repairing these fractures, the IN has a number of advantages over plate fixation.

The IN is stronger than a plate when used in a buttress fashion. Because it is intramedullary it undergoes much less bending stress than a plate located away from the center of the bone (neutral axis). Also, the area moment of inertia (a determinant of an object's ability to resist bending) of the cylindrical IN is much greater than that of a rectangular plate.

The IN can also be inserted in a semi-closed fashion greatly reducing chances of infection and preventing disruption of the "soft tissue envelope" surrounding the bone that is essential for rapid callus formation. The IN was originally locked in place using fluoroscopy to guide screw placement but a jig used in the new system allows "blind" placement of screws with very good accuracy.

A total of 176 clinical have been reported in 3 retrospective studies. The majority of injuries were comminuted femoral fractures with tibia and humeral fractures also represented. Approximately 97% of the fractures repaired had good to excellent results at follow-up. An overall complication rate of 11% was recorded. The most frequent complication reported was



screw hole failure, but with a recent design modification this weakness has been almost entirely eliminated. Sciatic impingement reported with intramedullary pin fixation is virtually impossible with the IN because the insertion technique results in deep recession within the trochanteric fossa and the locking screws prevent migration of the implant.

At MedVet we have used the IN to repair number of severe fractures. The IN technique offers excellent implant strength for comminuted fractures and our ability to insert the IN in a semi-closed fashion has meant rapid return of comfort and weight-bearing for our patients. While it does not completely replace the use of bone plates, it does greatly enhance our ability to provide the most effective and rapid means to patient recovery.

**Procedure**

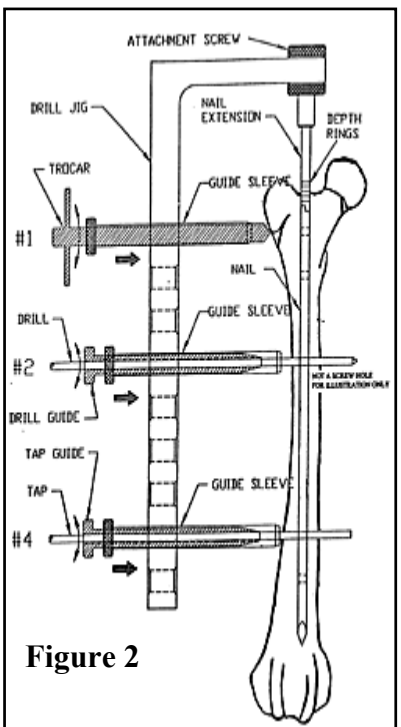
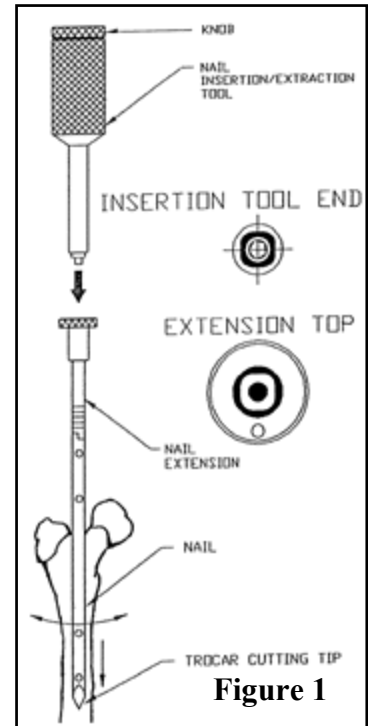
**Figure 1-** The nail extension is screwed into the nail and an inserting tool used to drive the nail into the reamed femoral canal. Depth rings on the nail extension help to determine level of nail insertion.

**Figure 2-** The inserting tool is removed and the jig screwed tightly to the nail extension. The jig is labeled so that proper screw insertion is ensured for different nail lengths. Screws are placed by a combination of tissue dissection, drilling through the drill sleeve, verifying screw length with depth gauge, tapping the drill hole, and inserting the screw. Rigid fixation of the jig to the nail insures proper screw placement. The jig is removed and closure of soft tissues is performed.

**Suggested Readings**

Dueland RT, Johnson KA, Roe SC, et al. Interlocking nail treatment of diaphyseal long bone fractures in dogs. *J Am Vet Med Assoc* 1999;214:59-66.

Durall I, Diaz MC, Morales I. Interlocking nail stabilization of humeral fractures. Initial experience in seven clinical cases. *Vet Compar Orthop Traumatol* 1994;3-8.



300 East Wilson Bridge Rd. Worthington, Ohio 43085  
 (614) 846-5800, (800) 891-9010, Fax (614) 846-5803  
 Copyright 2000. All Rights Reserved.